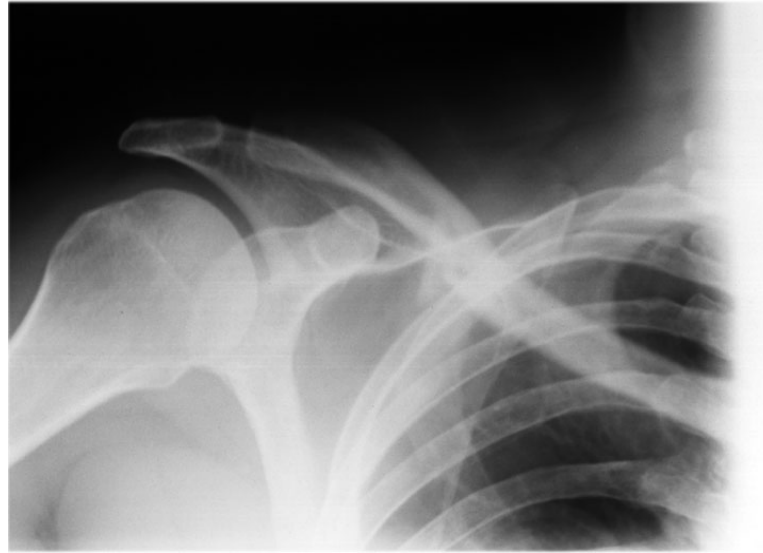


# TERMINOLOGY ACTIVITY

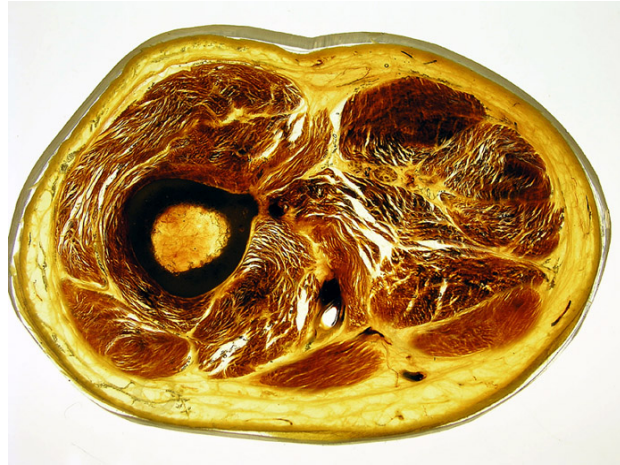In the following examples replace the underlined word(s) with the appropriate anatomical terminology



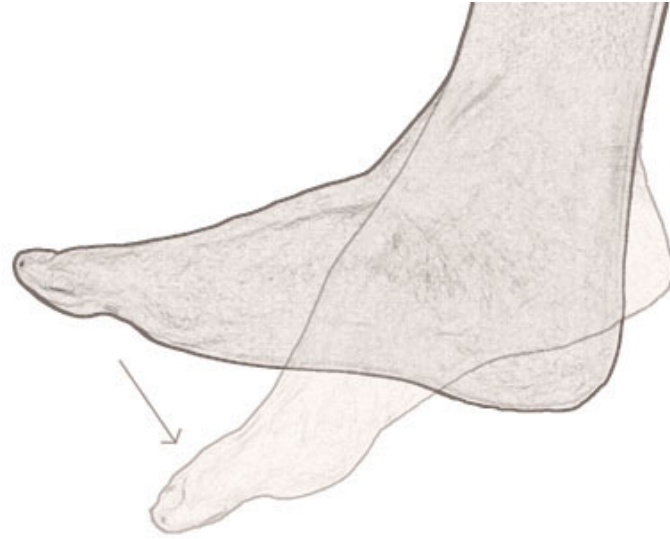This x-ray is a front view of Murry's broken collar bone.



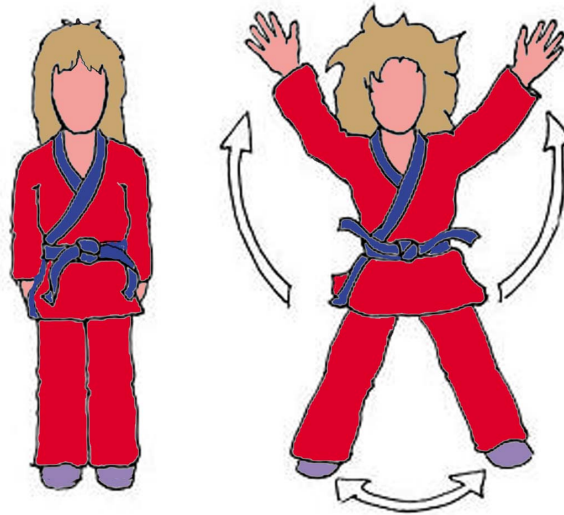
Jillian has broken the bottom of her funny bone




This is a cross section of  
an upper part of a thigh bone.



This is a side view of Ron bending and then straightening his foot.



When doing stride jumps the arms go out and then back while the elbows remain straight.



Jenny has hurt the  
end of her pinky finger