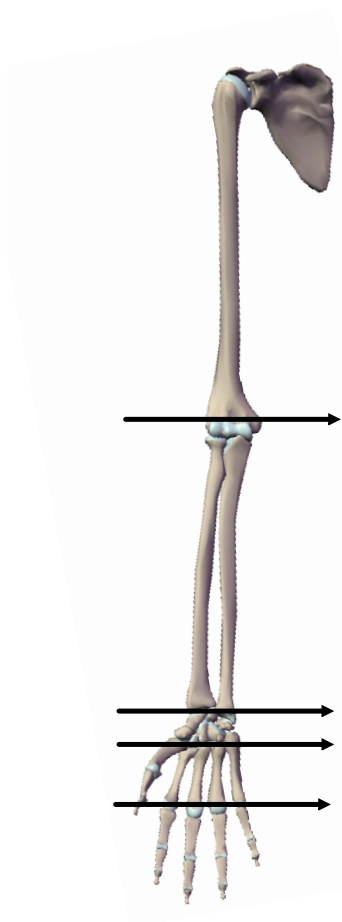


PAGE #29 & 31



Shoulder

clavicle
scapula
humerus

ulna
radius

PAGE #33

carpals

metacarpals

PAGE #33

phalanges

and features...

clavicle

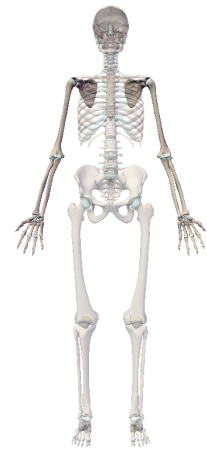- acromial end
- sternal end

scapula

- acromion
- coracoid process
- superior angle
- spine
- medial margin
- lateral margin

humerus

- greater tubercle
- head
- shaft
- medial epicondyle
- lateral epicondyle
- olecranon fossa
- trochlea
- capitulum



Attachments

ANATOMY - Skull Bones.mp4